

eMag FEATURED STORY

Specs ...

- 1,000-2,000 words by board-certified veterinary specialist or expert
- URL link
- EPS logo



LOG
...k-read format

PODCASTS
CE training on the run

OUT

MORE INFO

PS // 17
...nique and amazing tips and
...e've learned and need to share

MEMBERSHIPS // 17

PROVIDER SPOTLIGHT // 18
Check out what others are doing
in our community



QUARTERLY BEAT / DECEMBER 2019

DIAGNOSIS & MANAGEMENT OF CONSTIPATION IN CATS

SUSAN LITTLE, DVM, DABVP (FELINE)
@catvetsusan, catvet@vin.com

In the VETgirl Real-Life Rounds webinar, "Management of Constipation in Cats," the diagnostic workup and approach for treatment of constipation in cats. [Learn](#)

KEY HIGHLIGHTS

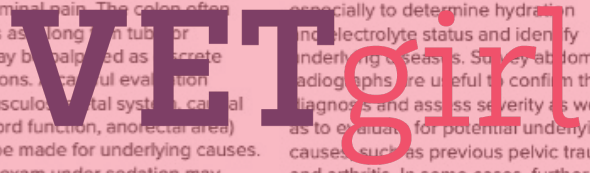
Constipation is the infrequent and difficult evacuation of feces with retention of feces within the colon and rectum. Obstipation is intractable constipation. Some of the more common underlying causes of constipation include certain drugs, stressors, litter box aversion, difficulty in defecating (pain, neurologic problems), excessive fecal bulk, dehydration (e.g., associated with chronic kidney disease), intra- or extraluminal colon masses, narrowed pelvic canal, and idiopathic megacolon.

1 CLINICAL SIGNS AND DIAGNOSIS
The clinical signs of constipation are typically obvious to the owner, such as tenesmus, and scant hard dry feces, sometimes with blood. However, cats will also strain in the litter box due to lower urinary tract obstruction and owners may misinterpret this as due to constipation. Other clinical signs are non-specific, such as vomiting, inappetence, and lethargy.

Physical examination confirms the presence of large amounts of feces in the colon sometimes accompanied by abdominal pain. The colon often palpates as long, thin tubular feces may be palpated as discrete concretions. A careful evaluation (e.g., musculoskeletal system, spinal cord function, anorectal area) should be made for underlying causes. A rectal exam under sedation may



be necessary in some patients to evaluate for masses, pelvic fracture malunion, or anal gland abnormalities. A minimum database (complete blood count, serum chemistries/electrolytes, urinalysis) should be assessed, especially to determine hydration and electrolyte status and identify underlying diseases. Survey abdominal radiographs are useful to confirm the diagnosis and assess severity as well as to evaluate for potential underlying causes such as previous pelvic trauma and arthritis. In some cases, further



VETgirl, LLC | All rights Reserved

vetgirlontherun.com